
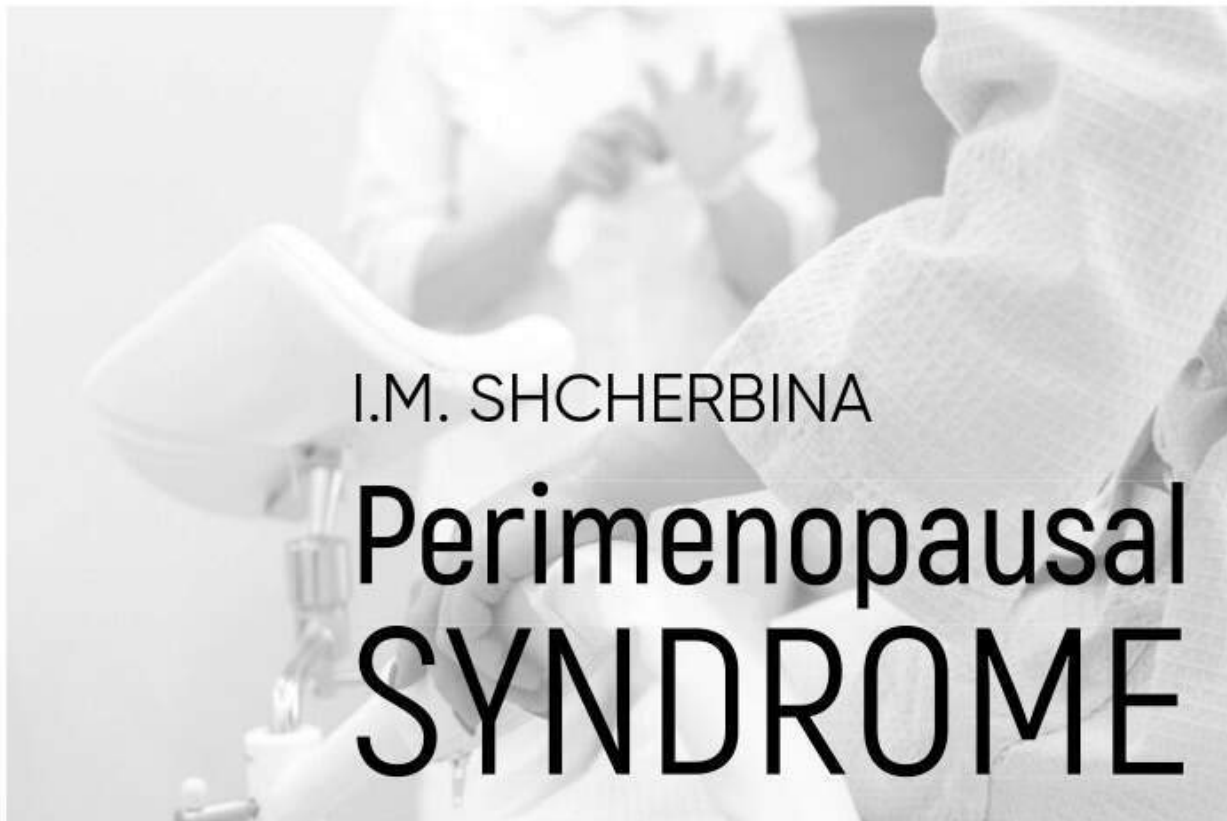

Perimenopausal syndrome: monograph

The monograph sets out modern ideas about the etiology and pathogenesis of perimenopause. Information on the features of the clinical manifestations of perimenopausal disorders, modern diagnostic methods, basic principles of therapy and prevention of perimenopausal systemic disorders are presented. The data of evaluating the effectiveness of the therapy, depending on the symptom complex of perimenopausal disorders, with the results of dynamic monitoring of the state of hormonal, immunological status, lipid metabolism, target organs during therapy are presented.  The monograph recommended for obstetricians-gynecologists, endocrinologists, internists, general practitioners of family medicine, undergraduate and postgraduate medical students.



I.M. SHCHERBINA

Perimenopausal SYNDROME

APPROVED

by the Academic Council of Kharkiv
National Medical University as a scientific
publication for students, masters, teachers
and practitioners of the system of institutions
of higher medical education in Ukraine
(letter dated January 20, 2021)

**Kyiv
Medicine
2021**

UDC 618.2/.7;618.1
LBC 57.16.,57.1j73
S53

*Approved by the Academic Council of Kharkiv National Medical University
as a scientific publication for students, masters, teachers and practitioners
of the system of institutions of higher medical education in Ukraine
(letter dated January 20, 2021)*

Edited by *I.M. Shcherbina* — Doctor of Medical Sciences, Professor
of the Department of Obstetrics and Gynecology № 1 of Kharkiv National
Medical University

Reviewers:

A.Yu. Shcherbakov — Doctor of Medical Sciences, Head of the De-
partment of Obstetrics and Gynecology № 1 of Kharkiv Medical Academy
of Postgraduate Education

A.M. Gromova — Doctor of Medical Sciences, Head of the Depart-
ment of Obstetrics and Gynecology № 1 of Ukrainian Medical Stomatolo-
gical Academy, Poltava

Shcherbina I.M. Perimenopausal syndrome : monograph. —
S53 Kyiv : AUS Medicine Publishing, 2021. — 160 p.
ISBN 978-617-505-845-9

The monograph sets out modern ideas about the etiology and pathogenesis of perimenopause. Information on the features of the clinical manifestations of perimenopausal disorders, modern diagnostic methods, basic principles of therapy and prevention of perimenopausal systemic disorders are presented. The data of evaluating the effectiveness of the therapy, depending on the symptom complex of perimenopausal disorders, with the results of dynamic monitoring of the state of hormonal, immunological status, lipid metabolism, target organs during therapy are presented.

The monograph recommended for obstetricians-gynecologists, endocrinologists, internists, general practitioners of family medicine, undergraduate and postgraduate medical students.

UDC 618.2/.7;618.1
LBC 57.16.,57.1j73

ISBN 978-617-505-845-9

© I.M. Shcherbina, 2021
© AUS Medicine Publishing, design, 2021

Contents

Introduction.....	5
Chapter 1. TERMINOLOGY AND CLASSIFICATION OF THE PERIMENOPAUSAL PERIOD	6
Chapter 2. EPIDEMIOLOGICAL ASPECTS OF THE PERIMENOPAUSAL PERIOD	9
Chapter 3. PATHOGENESIS OF THE PERIMENOPAUSE	15
Chapter 4. MORPHOFUNCTIONAL CHARACTERISTICS OF THE OVARIES IN PERIMENOPAUSE	25
Chapter 5. CLINICAL MANIFESTATION OF PATHOLOGICAL PERIMENOPAUSE	30
Chapter 6. DIAGNOSTICS	42
Chapter 7. GENETIC ASPECTS OF PERIMENOPAUSE. ANALYSIS OF HERITABILITY AND FORECASTING FEATURES OF THE PERIMENOPAUSAL PERIOD	60
Chapter 8. MODERN APPROACHES TO COMPREHENSIVE TREATMENT OF PERIMENOPAUSAL VIOLATIONS	68
Chapter 9. FUNCTIONAL STATE OF DIFFERENT SYSTEMS OF THE WOMAN'S BODY DURING THE PHYSIOLOGICAL COURSE OF PERIMENOPAUSE	77
Chapter 10. FEATURES OF THE FUNCTIONAL STATE OF THE BODY SYSTEMS IN WOMEN WITH NEUROVEGETATIVE AND PSYCHO-EMOTIONAL DISORDERS IN THE PERIMENOPAUSE	80
10.1. Functional state of the nervous system and psycho-emotional status	80
10.2. Immunoreactive relationships and nature of immune disorders	84
10.3. Features of the hormonal background and activity of biogenic amines.....	87
10.4. Indicators of lipid metabolism, LPO processes and antioxidant activity.....	89
10.5. The effectiveness of complex treatment and monitoring of patients with neurovegetative and psycho-emotional disorders.....	90
Chapter 11. UROGENITAL DISORDERS IN PERIMENOPAUSE	96
11.1. Indicators of urodynamic studies.....	96

CONTENTS

11.2. Features of immunoreactivity and the nature of immune disorders in patients with urogenital violations.....	99
11.3. Indicators of the level of hormones and biogenic amines.....	102
11.4. Characteristics of lipid metabolism.....	103
11.5. The effectiveness of complex treatment of patients with urogenital disorders.....	104
Chapter 12. PERIMENOPAUSAL METABOLIC SYNDROME.....	110
12.1. Immunological aspects of metabolic disorders in perimenopause.....	110
12.2. Hormonal status of patients with metabolic perimenopausal disorders.....	114
12.3. Lipid metabolism study results.....	117
12.4. Complex treatment and monitoring of patients with metabolic disorders.....	119
Chapter 13. DISORDERS OF THE MUSCULOSKELETAL SYSTEM IN THE PERIMENOPAUSE.....	125
13.1. Features of immunoreactivity and the nature of immune violations in patients with musculoskeletal disorders in the perimenopause.....	125
13.2. Indicators of the level of hormones and biogenic amines.....	129
13.3. Lipid metabolism indicators.....	131
13.4. The effectiveness of complex treatment of patients with musculoskeletal disorders.....	132
References.....	141

Introduction

Due to the rapid growth in the number of older people, the increase in life expectancy and the continued active participation of this contingent in many areas of activity, the study of the pathophysiology of the perimenopausal period is of great medical and social importance. The perimenopausal period is the stage of a woman's life between youth and old age, when, against the background of involution of the higher nerve centers and the reproductive system, the body is reorganized and adapted to new conditions of existence.

The proportion of women over 50 has tripled over the past 100 years, and life expectancy has increased from 50 to 81.5 years. Obviously, in the first half of the twenty-first century, the average age of the world's population will grow much faster and the number of older people by 2050 may be almost 2 billion people. In Ukraine, over the years of independence, the number of the female population over 49 years old in absolute terms has decreased by 11 %, the proportion of this contingent of women concerning to the entire female population of the country increased from 20 % to 22 %. That is, a significant number of women will spend a third of their lives in perimenopause.

During this period of life, the aging process begins, during which the woman moves from the reproductive stage to the non-reproductive one.

With the onset of the perimenopausal period, new socio-economic, general medical and psychological problems arise associated with the adaptation of women to the neuroendocrine restructuring of the body. Morbidity, incidence of disability, mortality in this age period are significantly higher than in other age groups.

The arsenal of medicines intended to help women in perimenopause is currently large enough. However, the clinical manifestations of perimenopausal disorders require a reasoned analysis of the effectiveness of existing types of therapy, individualization of treatment and methods of monitoring the condition of this category of patients.

Chapter 4

MORPHOFUNCTIONAL CHARACTERISTICS OF THE OVARIES IN PERIMENOPAUSE

The ovarian biopsies were the object for morphological study, which were obtained during the surgical treatment of patients with various gynecological pathologies. The material was subjected to macroscopic and microscopic examination, paraffin sections 10 to 15 microns thick were stained with hematoxylineosin, picrofuchsin according to Van Gieson.

In patients with the physiological course of the perimenopausal period, the morphological picture of the biopsy material was characterized by monotonous extinction of the folliculogenesis process with impaired formation of a full-fledged pool of follicles from primordial to mature Graafs with a decrease in synthetic processes in granulosa and theca tissue cells (Fig. 4.1).

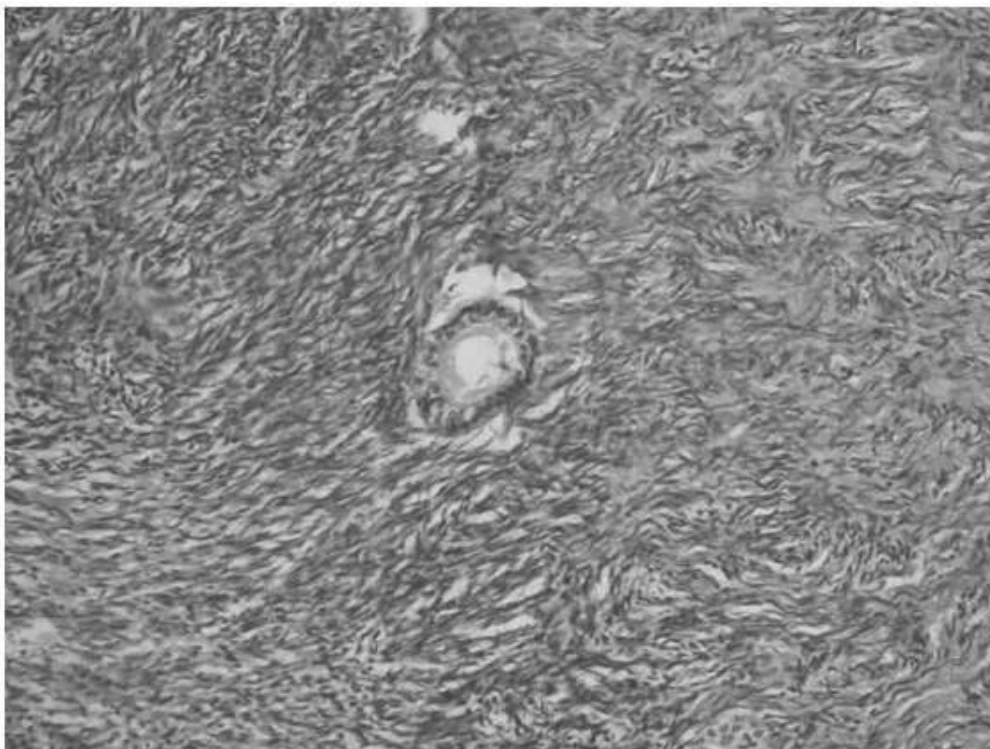


Fig. 4.1. Primary follicle. Observation No. 17. Staining with hematoxylin-eosin $\times 200$

Thus, microscopic examination revealed the presence of collagen fibers in the albuminous membrane of the gonads, which are stained with microfunsin according to van Gieson in a reddish color. A significant thickening of the ovarian tunica albuginea with the development of coarse fibrous connective tissue in it is detected in a small proportion of cases.

When studying the morphostructure of ovarian tissue in patients with neurovegetative and psychoemotional disorders in perimenopause, there was a monotonous extinction of folliculogenesis, moderate atrophy of ovarian tissue. There were follicular cysts, the inner membrane of which consists of 2.5 layers of cells. In two women, follicular cysts contained connective tissue (follicular atresia) (Fig. 4.2).

There were single primordial follicles. There was no luteinization of stromal cells, there were endometrioid heterotopies. The vessels in most cases retained their structure, in part, their lumens are moderately narrowed, with symptoms of hyalinosis and sclerosis of the walls.

When studying the ovarian tissue in patients with urogenital disorders, a rather pronounced extinction of folliculogenesis was observed, single atretic follicles, follicular cysts were determined in the cortical layer, the inner surface of which consisted of 1 to 2 layers of the epithelium, and

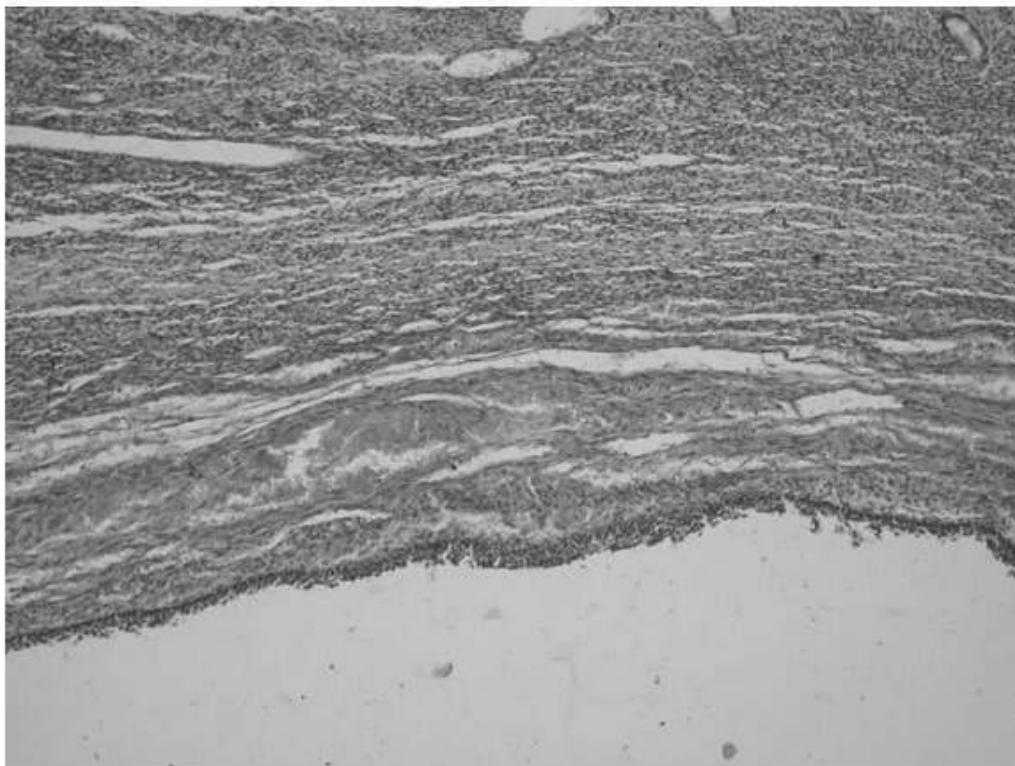


Fig. 4.2. The wall of the follicular cyst with hemorrhage into the theca tissue and the presence of connective tissue elements in it. Observation No. 9. Staining with hematoxylin-eosin $\times 100$

yellow and white bodies with hyalinosal phenomena were found, displacing stromal tissue (Fig. 4.3).

In the last of the above, focal hyperplasia with areas of lymphoid infiltration was sometimes found, the vessels were fragmented, their walls were thickened, the lumens were narrowed.

When studying the morphological picture of ovarian tissue in patients with metabolic disorders, disorders of folliculogenesis were noted, and a rather frequent appearance of theca-luteal and granulosa-luteal cysts of the corpus luteum. Primordial and primary follicles were practically absent. Attention was drawn to the presence of foci of luteinized theca cells in the ovarian stroma. The vascular endothelium was focally located like a "palisade", the lumens were sharply narrowed, impression was created of a greater severity of sclerotic changes in ovarian vessels in women with metabolic disorders in perimenopause than in patients of other clinical groups (Fig. 4.4).

When studying the morphostructure of the gonads in this group of patients against the background of progressive atrophy of the ovarian tissue and the most pronounced inhibition of folliculogenesis, ovarian follicles are represented by single atrophic small follicles, primordial and primary ones are absent, some patients had some solitary follicular cysts with severe atrophy of granulosa cells and hyperplasia of theca tissue (Fig. 4.5).

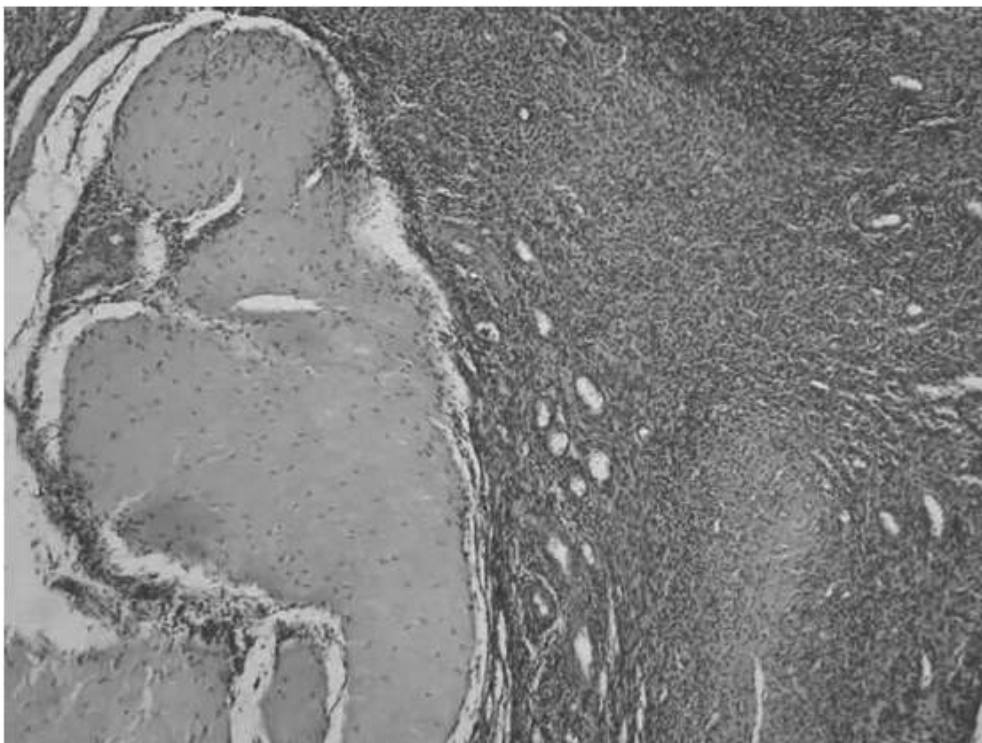


Fig. 4.3. Yellow body with symptoms of hyalinosis. Observation No. 5. Staining with hematoxylin-eosin $\times 100$

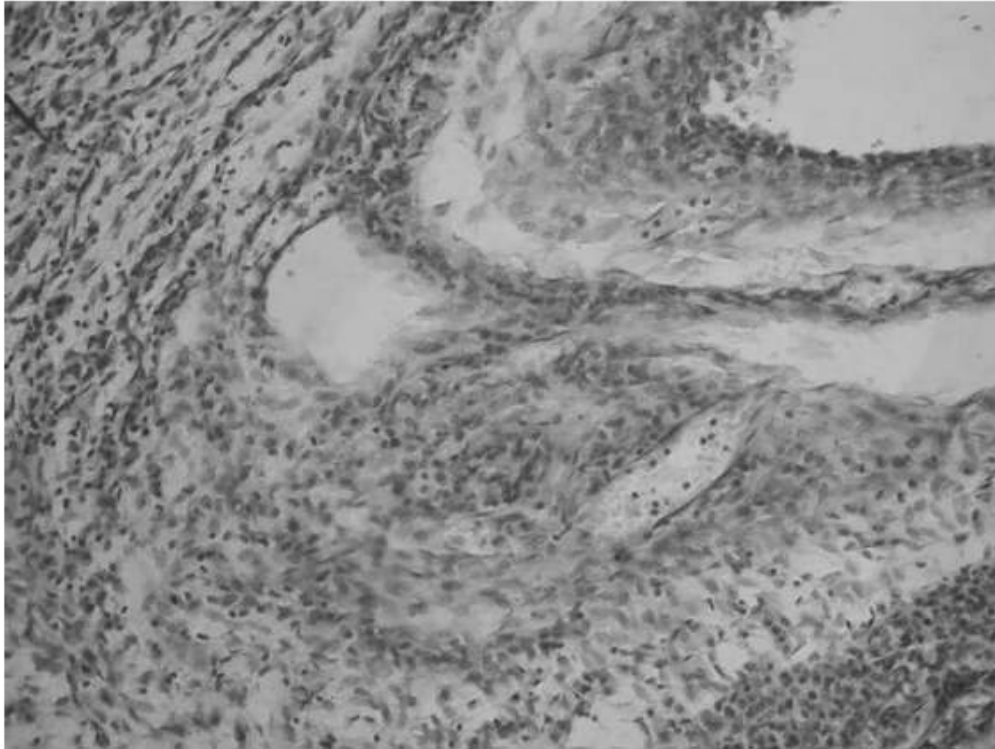


Fig. 4.4. Granulosoluteic cyst of the corpus luteum. Observation No. 16. Staining with hematoxylin-eosin $\times 100$

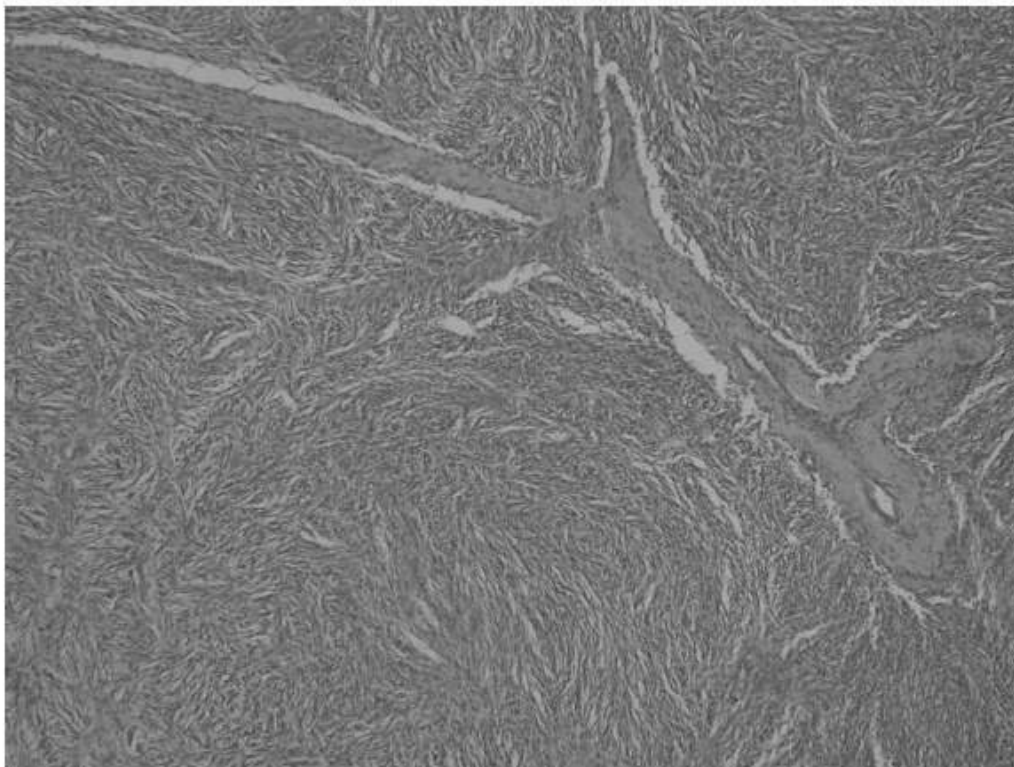


Fig. 4.5. Compaction of the stroma, absence of follicles, hyalinosis, vascular sclerosis. Observation No. 19. Staining with hematoxylin-eosin $\times 100$

There were white and yellow bodies with symptoms of hyalinosis and sclerosis, vessels with pronounced hyalinosis and sclerosis of the walls, some vessels with lumen obliteration.

Thus, studying the morphostructure of the ovaries in all clinical forms of perimenopausal disorders, we noted a monotonous extinction of folliculogenesis with pronounced atrophy of ovarian tissue in varying degrees. The most pronounced morphological changes in ovarian tissue were found in metabolic disorders. So, in this group of patients, the appearance of thecaluteal and granulosa-luteal cysts of the corpus luteum was observed, which, apparently, is explained by the existing hyperandrogenism characteristic of this syndrome. Noteworthy is the appearance of foci of luteinized theca cells in the ovarian stroma, pronounced sclerotic changes in the vascular network. The morphological picture in the group with neurovegetative and psychoemotional disorders is similar, however, there is no luteinization of stromal cells, and sclerosis of the ovarian vessels is not pronounced. In the group with urogenital and musculoskeletal disorders, against the background of the most pronounced suppression of folliculogenesis and atrophy of ovarian tissue, yellow and white bodies with symptoms of hyalinosis are found, displacing stromal tissue. The vessels are fragmented, the walls are thickened, the lumens are narrowed, obliterated in some places.

ridmi
ТВІЙ УЛЮБЛЕНИЙ КНИЖКОВИЙ

КУПИТИ