




**Obstetrics and Gynecology: in
2 volumes. Volume 1.
Obstetrics: textbook**

Under current conditions in the sphere of improvement of the quality of student training at higher medical education establishments and deepening of their knowledge in the field of obstetrics it becomes absolutely necessary to publish textbooks, which cover the issues of obstetrics and correspond to current education programs.  The textbook has been created according to the obstetrics curriculum and in accordance with the Bologna process requirements.  The book describes the latest achievements of world obstetric science, deals with physiological aspects of pregnancy and childbirth, major factors of etiology, pathogenesis, clinical presentation, diagnosis, treatment and prevention of diseases during pregnancy, labor and postpartum period.  For students of higher medical education establishments.

OBSTETRICS & GYNECOLOGY

IN TWO VOLUMES

TEXTBOOK

Edited by
Academician of the NAS of Ukraine,
Professor V.I. Gryshchenko,
Professor M.O. Shcherbina

Volume 1

Obstetrics

SECOND EDITION

ALLOWED

by the Ministry of Health of Ukraine
as a textbook for students of higher medical
education establishments

PUBLISHED

in accordance with the Order of the Ministry
of Health of Ukraine No. 502 of 22 June 2010
as a textbook for students of higher medical
education establishments

KYIV
AUS MEDICINE PUBLISHING
2018

UDC 6182/7
LBC 48.76;57.16ya73
O-25

*Allowed by the Ministry of Health of Ukraine as a textbook for students
of higher medical education establishments*

*Published in accordance with the Order of the Ministry of Health of Ukraine
No. 502 of 22 June 2010 as a textbook for students of higher medical
education establishments*

Authors:

V.I. Gryshchenko — Academic of the National Academy of Sciences of Ukraine (NASU);
M.O. Shcherbina — Professor;
B.M. Ventskiivskiyi — Corresponding Member of the National Academy of Medical Sciences of Ukraine (NAMSU);
V.V. Kaminskyi — Corresponding Member of the NAMSU;
L.B. Markin — Corresponding Member of the NAMSU;
L.V. Potapova — Professor;
V.V. Lazurenko — Professor;
O.V. Mertsalova — Professor;
O.P. Lipko — Professor;
I.M. Shcherbina — Professor;
M.G. Gryshchenko — Professor

Reviewers:

A.M. Gromova — Doctor of Medicine, Professor, Head of the Department of Obstetrics and Gynecology No. 1 of Ukrainian Medical Stomatological Academy;
B.F. Mazorchuk — Doctor of Medicine, Professor of the Department of Obstetrics and Gynecology No. 1 of Pirogov Vinnytsya National Medical University

Obstetrics and Gynecology : in 2 vol. : textbook. Vol. 1. Obstetrics /
O-25 V.I. Gryshchenko, M.O. Shcherbina, B.M. Ventskiivskiyi et al. ; edited by
V.I. Gryshchenko, M.O. Shcherbina. — 2nd edition. — K. : AUS Medicine
Publishing, 2018. — 392 p.

ISBN 978-617-505-693-6

Under current conditions in the sphere of improvement of the quality of student training at higher medical education establishments and deepening of their knowledge in the field of obstetrics it becomes absolutely necessary to publish textbooks, which cover the issues of obstetrics and correspond to current education programs.

The textbook has been created according to the obstetrics curriculum and in accordance with the Bologna process requirements.

The book describes the latest achievements of world obstetric science, deals with physiological aspects of pregnancy and childbirth, major factors of etiology, pathogenesis, clinical presentation, diagnosis, treatment and prevention of diseases during pregnancy, labor and postpartum period.

For students of higher medical education establishments.

UDC 6182/7
LBC 48.76;57.16ya73

ISBN 978-617-505-693-6

© V.I. Gryshchenko, M.O. Shcherbina, B.M. Ventskiivskiyi,
V.V. Kaminskyi, L.B. Markin, L.V. Potapova,
V.V. Lazurenko, O.V. Mertsalova, O.P. Lipko,
I.M. Shcherbina, M.G. Gryshchenko, 2014, 2018
© AUS Medicine Publishing, design, 2018

Chapter 1

FERTILIZATION, EMBRYOGENESIS, CRITICAL PERIOD OF ONTOGENESIS

FERTILIZATION

Fertilization is the process of merging of male reproductive cells (sperm cells, spermatozoa) with a female one (egg cell), resulting in formation of a fertilized egg — zygote.

Gametogenesis

Gametogenesis is the development of germ cells. Sex cells form and ripen in the gonads: sperm — in the testicles, egg cells — in the ovaries. Gametogenesis in males and females has some common stages: 1) formation of primary germ cells, 2) reproduction of sex cells in the gonads, 3) growth of germ cells, 4) meiosis, 5) maturation.

Spermatogenesis is the development of male sex cells — sperm.

Among millions of spermatozoa only a few reach their goal and fertilize the egg cell. A mature human sperm cell is 50–60 microns long, consists of a head, a neck and a tail. The head is oval, flattened, contains a condensed haploid nucleus, an acrosome (a secretory granule containing hydrolytic enzymes that enable the sperm cell to penetrate through the ovocyte shell). The neck contains proximal centrioles, which contribute to the process of crushing the fertilized egg cell. Part of the tail is surrounded by mitochondria that produce energy, i.e. synthesize adenosine acid or adenosine triphosphate (ATP). Flagellum (an axial thread-like axonema or an axial beam) consists of two central microtubules surrounded by equidistant double microtubules, around which dense fibers are located. Dense fibers are rigid, they promote vigorous movements of the flagellum. The tail ends with a thin thread. Mature sperm cells are negatively charged, so their collision and agglutination occur only in acidic medium. Their speed is 3 mm/min. In the vagina spermatozoa remain mobile for 1–2 hours (in acidic medium they die soon) and in the cervical mucus — during 38–48 hours. Spermatozoa are capable of fertilization at a temperature of 0 to 40 °C.

Development of sperm cells consists of several stages. Spermatogenesis begins after puberty and lasts continuously in the seminiferous tubules of the testis.

Spermatogonia are immature germ cells, located on the periphery of the seminiferous tubules (in the basal area). There are two types of spermatogonia — Type A and Type B. Type A spermatogonia contain dark nuclei (these cells replicate to en-

Chapter 1

sure a constant supply of spermatogonia to fuel spermatogenesis) and pale nuclei (they divide by mitosis to produce Type B cells). *Primary spermatocytes* divide at the first stage of meiosis. *Secondary spermatocytes* have 22 autosomes and one X- or Y-chromosome and divide at the second phase of meiosis. *Spermatids* are characterized by a haploid set of chromosomes. At the stage of gamete formation cytoplasmic bridges must break to provide sperm ribonucleic acid (iRNK) of the X-chromosome with information. Spermatogenesis takes 65 days. Final differentiation occurs within 2 weeks. Sperm mature and accumulate in the epididymis. An important role in spermatogenesis is played by sustaining (Sertoli) cells. They form a hemotesticular barrier, which separates germ cells from toxins and antigens and performs trophic function — phagocytosis of cytoplasmic remnants, degenerated cells secrete fluid in the seminiferous tubules.

Hormonal control of spermatogenesis: sexual maturation is regulated by a special part of the central nervous system (CNS) neurons, which are insensitive to sex hormones. Neurosecretory cells of the hypothalamus synthesize gonadoliberin, and the pituitary gland, in its turn, — follitropin and lutropin. Follitropin activates Sertoli cells that secrete androgen-binding protein (responsible for maintaining a high level of testosterone), inhibin (blocks follitropin synthesis), estrogens (reduce testosterone synthesis), transferrin (transports iron in the spermatogenic epithelium and acts as a mitogenic factor), plasminogen activators. Lutropin stimulates interstitial glandulocytes (Leydig cells) synthesis and secretion of testosterone and estrogen.

Ovogenesis occurs in several stages, most of which take place in the ovary (in the first half of the menstrual cycle). Ovocyte is an immature ovum.

Ovum is a female reproductive gamete with a diameter of about 100 microns and a specific structure. Radiant crown (*corona radiata*) is a collection of follicular cells surrounding the egg. The cells encompassing egg are called oviparous tubercles (*cumulus oophorus*).

The pellucid zone (*zona pellucida*) is adjacent to the plasma membrane and is composed of glycoproteins, two of which are sperm receptors. The plasma membrane is adapted to fertilization. Cortical substance of the cytoplasm has a very ordered structure and includes microfilaments required for division.

Cortical granules (approximately 15,000 pcs.) are homologous to acrosomes, contain proteolytic enzymes, mucopolysaccharides, hyaline layer protein and, thus, block polyspermia in early blastomeres. In addition to the cytoplasm there are nutrients, ribosomes, ribonucleic acid (RNA), morphogenetic factors, etc.

Primary germ cells migrate to the gonads and form *ovogonia* that divide mitotically and differentiate into primary ovocytes.

Primary ovocytes enter the prophase of meiosis during the first 3—8 months of gestation. The division in this phase is terminated before the onset of puberty. Ovocytes enter the stage of growth (accumulation of RNA, proteins, ribosomes, glycogen, lipids, emergence of cortical granule membranes). At the same time follicles are developing, first there is a primordial follicle (the thin layer of cells around the ovocyte), which then turns into a follicle that grows, and the next stage is the formation of antral follicles (cavities with follicular fluid). It should be noted that only a small proportion of follicles at each stage pass to the next stage: of 400—500 thousand primary follicles 33—40 thousand enter the maturing stage, and only 450—500 complete it.

Fertilization, Embryogenesis, Critical Period of Ontogenesis

A secondary ovocyte and *the first polar body* are formed as a result of the first stage of meiosis. This phase of development is called maturation and involves 15–25 follicles, of which only one “survives”. This follicle is undergoing significant development (cell division, Graafian vesicle formation). A secondary ovocyte is characterized by a haploid number of chromosomes. It enters the second stage of meiosis. At this stage the corpus luteum is formed.

Hormonal control of ovogenesis: in response to gonadoliberin secretion by the hypothalamus the adenohypophysis synthesizes and secretes follitropin and lutropin. Follitropin stimulates mitosis, follicular cells produce estrogen and inhibin that leads to secondary ovarian follicle formation. Lutropin increases the synthesis of androgens, which begins luteinization of the follicular cells, contributes to the first phase of meiosis, activates proteolytic enzymes, causing rupture of the follicle.

Fertilization

Fertilization occurs in the ampullar section of the fallopian tube. Sperm, deposited after sexual intercourse in the back of the vault of the vagina, by means of their own movements fall into the fallopian tubes, where due to muscle contractions and directional movement of oviduct reach capsules.

Merging of germ cells in the female internal reproductive organs is called *internal fertilization*. Stages of fertilization are *penetration of sperm* into the egg and *nuclear fusion* of both gametes.

Ejaculate flows into the vagina in an amount from 2 to 5 ml. Under normal conditions ejaculate contains 30 to 100 million sperm in 1 ml, of which only 100 sperm cells reach the ampullae of the uterine tube. Sperm transport lasts for 5–30 hours. Fertilization usually occurs within the first 12 hours after ovulation. Spermatozoa in the female genital organs retain the ability to fertilize for 1–2 days.

As sperm cells penetrate the egg shell, an important role is played by acrosome reaction. As the sperm approaches the pellucid zone of the egg, which is necessary for initiating the acrosome reaction, the membrane surrounding the acrosome fuses with the plasma membrane of the ovocyte, exposing the contents of the acrosome. The contents include surface antigens and numerous enzymes, which are responsible for breaking through the egg’s tough coating and making fertilization possible.

Sperm cells that have just entered the female genital organs are not yet able to perform acrosome reaction to connect to the egg. Such an ability is acquired when sperm cells are exposed to specific changes called *capacitation*. Capacitation is influenced by substances secreted by the mucous membrane of the uterus and fallopian tubes.

The plasma membrane of sperm and egg cells leads to activation of the latter, which is a complex set of events that include cortical reaction and formation of an accepting tubercle, nucleus stimulation, etc. In the place of attachment the egg cortex is involved, and often with the accepting tubercle formation.

Ovoplasm of the accepting tubercle gets under the plasma membrane of the sperm, wraps around its nucleus and organelles, and then they start to move to the base of the accepting tubercle, while the plasma membrane of the sperm remains on the surface.

The sperm head is immersed in the cytoplasm, being guided by the closest middle part into the egg. Moving to the place of fusion with the egg cell nucleus, the sperm nucleus gradually transforms into a male pronucleus, its chromatin loosens and

Chapter 1

disperses, the nuclear envelope breaks into separate vesicles, and the pronucleus membrane is formed again.

These transformations take place simultaneously with the completion of division, maturation and formation of female pronucleus. Both pronuclei converge in the center of the egg, which is the final stage of the fertilization process.

Blastogenesis

Blastogenesis is a stage of development of an embryo after fertilization. This stage combines the processes that occur after fertilization to form the so-called germ layers. During embryonic and fetal life (during organogenesis) separate organs and systems are formed of these layers.

After fertilization the zygote (fertilized egg) begins to divide mitotically, with daughter cells (blastomeres) formation as a result of this cleavage (Fig. 1).

After a certain number of repeated divisions that occur gradually a cellular nodule is formed, which is the accumulation of a large number of blastomeres. The tubercle has a spherical shape, its surface is covered with furrows, looks like a raspberry (this stage of development is called morula). Formation of a morula is the first period of blastogenesis.

The second period of blastogenesis (blastulation) is characterized by emergence of a cavity (blastocyst) within the morula and limitation of this cavity with a cell wall (blastoderm), as a result a blastula is formed (see Fig. 1). At the same time embryoblast cells assemble on one pole of the blastocyst, trophoblast cells form its outer shell.

The third period of blastogenesis is called gastrulation, during which a complex structure is formed — gastrula. During this period, the first two germ layers are formed — ectoderm and endoderm.

In the fourth period the third layer is formed — mesoderm. After the period of blastogenesis the germ layers form organs and the whole organism during organogenesis.

Thus, embryonic development is a stage of organism development from fertilization to completion of the basic processes of organogenesis lasting up to 8 weeks.

Implantation

Implantation is immersion of the embryo in the mucous tunic of the uterus. Trophoblast secretes proteolytic enzymes that melt the endometrium, which makes it possible for an embryo to penetrate deep into the endometrium and get nourishment. Implantation begins on the 5th—6th day after fertilization. A trophoblast consists of two layers: the inner (cytotrophoblast, or Langhans cells) and the outer (plasmodiotrophoblast). The embryo is fully immersed in the lining of the uterus until the 12th day after fertilization and trophoblast provides it with nutrients from the mucosa and secretion of the uterine glands (histiotrophic nutrition). At the following stages of embryo development the cytotrophoblast becomes a chorionic membrane and the plasmodiotrophoblast fuses with mucosa. In the plasmodium there form cracks, the first intervillous spaces. In the chorionic plate there begin to appear the primary fibers of chorion (chorionic villi) created by the cytotrophoblast cell surrounded by plasmodiotrophoblast. From the mesoderm that lines the inner wall of the trophoblast (chorion membrane) and gives rise to the primary villi there penetrate strips of the mesenchymal tissue, forming their stroma. Chorionic villi are initially formed on the

Fertilization, Embryogenesis, Critical Period of Ontogenesis

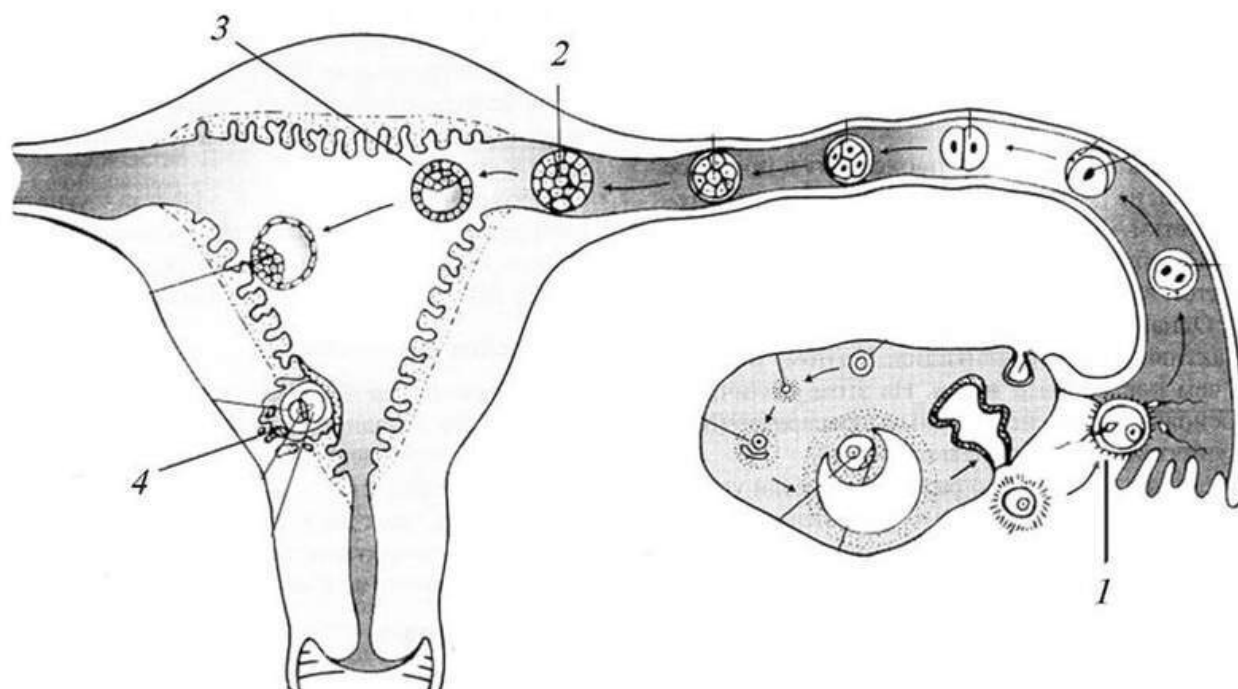


Fig. 1. Fertilization and implantation:
1) fertilization; 2) morula; 3) blastula; 4) implantation

entire surface of the chorionic membrane (villous chorion), later they remain only in places where there is placenta (chorion frondosum). The other part of the surface of the chorion is smooth — its villi disappear (smooth chorion — *chorion laeve*).

EMBRYOGENESIS

Along with the trophoblast there develops the embryoblast. Its development begins in the fallopian tubes and is greatly enhanced after implantation in the uterus. The cells surrounding the blastocyst cavity after implantation become a mesoblast. In one segment of the blastocyst there are formed clusters of cells, in which there are two bundles: ectoblast and endoblast. In the center of these nodules a cavity is soon formed and the ectoblast becomes an ectoblastic vesicle and the endoblast — an endoblastic vesicle. The ectoblastic vesicle is connected with the trophoblast by means of a crus. The ectoblastic vesicle forms the amniotic cavity. The walls of the cavity become amnion (amniotic fluid). The endoblastic vesicle is located closer to the center. It turns into the yolk cavity. Cells of the ectoblast and endoblast located between the amniotic and yolk sacs form the embryo anlage.

As the exocoelomic cavity increases, mesenchymal cells are pushed from one side to the chorion (trophoblast), from the other side — to the amniotic and yolk sacs and to the embryo, which is located between them. The walls of the sacs and chorion become double-layer. The embryonic anlage is formed of three germ layers: ectoderm, mesoderm and endoderm. These three layers form all tissues and organs of the fetus.

Mesodermal cells that have penetrated through the germinal streak migrate in the lateral direction and form a continuous layer with a thickness of several cells. As a result of cell proliferation, migration and their subsequent aggregation somites are

Chapter 1

formed (dorsal mesoderm) in the direction from the cephalic pole to the caudal pole of the embryo. A new pair of somites is formed after a certain period of time. In humans, this interval is on average about 6.5 hours.

Sclerotome. Under the influence of the chord and neural tube the cells of the ventromedial part of the somite (sclerotome) multiply rapidly and come out of the somite, surrounding the chord and ventral part of the neural tube. The cells that came out differentiate into cartilage and form the future vertebrae, ribs, shoulder blades.

Myotome and dermatome. In the dorsolateral part of the somites there is differentiated an internal layer of cells — the myotome that forms the skeletal muscles, and an external layer — the dermatome, an anlage of the connective tissue of the skin.

Nephrotome. Laterally to the somites the intermediate layer is represented by an accumulation of cells of the so-called intermediate mesoderm (nephrotome) — an anlage of the urinary and genital systems.

Lateral mesoderm. More laterally the mesoderm is located (mesoderm of the lateral plate), split into two layers: dorsal — somatic mesoderm (serous membrane) and ventral — visceral layer or splanchnic mesoderm (heart, adrenal cortical substance, etc.).

Allantois. Simultaneously with the development of membranes at the early stages an outgrowth — allantois (allantoid membrane) — is formed from the rear end of the embryonic primary gut. The allantois is connected with the villous membrane by means of the same crus as the amniotic sac with the trophoblast. Through the allantois vessels run from the body of the embryo to the villous membrane; these vessels grow into each chorionic villus. This is an important process — chorionic vascularization. Since this moment there develops allantoic circulation of the embryo, which provides intensive exchange between the embryo and the mother's body.

Amnion. As pregnancy progresses, the amniotic cavity is rapidly increasing, fluid is accumulating in it, its wall (amnion) is moving closer to the chorion and in the end is adjacent to it. The blastocyst cavity disappears. The embryo, localized between the amnion and yolk sac, is being drawn into the amniotic cavity and gradually becomes completely immersed in it. As the amniotic cavity increases, the yolk sac decreases, its vessels become empty, its walls atrophy. Since this moment the amnion becomes a closed sac containing the embryo surrounded by amniotic fluid.

With increasing gestation term the amniotic cavity further enlarges, the amnion is adjacent to the chorion, lines the fetal surface of the placenta, goes onto the umbilical cord, covering it in the form of a case, and merges in the area of the navel with the outside cover of the embryo. Amnion is a thin shell formed of the epithelium and connective tissue membrane, consists of layers formed of the mesenchyme. The amniotic epithelium (cylindrical and cubic) participates in the formation and metabolism (withdrawal) of amniotic fluid. Amnion and smooth chorion are responsible for ensuring the optimum composition of membranes.

Amniotic fluid. Amniotic fluid fills the cavity of the amnion, its amount by the end of pregnancy reaches 0.5—1.5 l. Amniotic fluid is formed as a result of amniotic epithelium secretion. It can also be partially formed by transudation of fluid from the maternal blood vessels. Excess amniotic fluid is removed through the intercellular canaliculi and pores in the amnion and smooth chorion. The process of amniotic fluid exchange — secretion, resorption — is intensive. This ensures constant composition of the amniotic

Fertilization, Embryogenesis, Critical Period of Ontogenesis

fluid, which is the habitat of the fetus. Fetal urine, epidermis cells, products of secretion of the skin sebaceous glands and prenatal hairs get into the amniotic fluid.

The amniotic fluid is composed of proteins, fats, lipids, carbohydrates, potassium, sodium, trace elements, urea, hormones, lysozyme, lactic and other acids, enzymes, biologically active substances that promote uterine contractions and affect the clotting of blood, antigens, immunomodulating factors, etc. Formation of the amniotic fluid is particularly intensive during the first months of pregnancy. By the end of pregnancy term as the fetus grows there is observed a relative decrease in its quantity.

Amniotic fluid is of great physiological significance:

- 1) it creates conditions for free development of the fetus and its movements;
- 2) protects the body of the fetus from adverse external influences;
- 3) is involved in metabolism of the fetus;
- 4) prevents cord compression;
- 5) promotes the normal course of labor.

Thus, the fetus is surrounded by three membranes: decidual membrane, chorion, and amniotic fluid. The decidual membrane — maternal — is formed of the uterine lining, the chorion and amniotic fluid are formed of the fetal mucous membrane.

Placenta

Placenta is a provisional organ formed during pregnancy. It provides connection between the body of the fetus and the mother. Placenta replaces the function of the lungs, digestive system, kidneys, skin and other organs of the fetus. Formation of the placental tissue involves the maternal tissue — the basal part of the decidua and fetal membrane derivatives — the trophoblast and chorion. In the formation of the chorion, and afterwards of the placenta there are distinguished three periods:

- 1) previllous (7th—8th day of development);
- 2) villi formation (50th day);
- 3) cotyledon formation (50th—90th day).

Chorionic villi, which are the major component of the placenta, are dendriform. The vessels in the large villi divide as they are branching. In the final villi there are only capillary loops. As pregnancy develops, the villi area increases, thus increasing the contact area of the maternal and fetal blood flow. The maternal blood flow is separated from the fetal one by means of the syncytiocapillary membrane. This boundary surface in a mature placenta is much greater than the size of the body surface of an adult and makes 12—14 m².

Sporadic villi penetrate into the maternal tissue and are called fixing or anchoring. Most villi are immersed directly in the maternal blood circulating in the intervillous space. The surface of the villi is covered with two layers of epithelium. The external layer — syncytium or plasmotrophoblast — consists of protoplasmic mass without cell membranes, which contains the cell nuclei. On the surface of the syncytium there are microvilli that increase the active surface. Under the syncytium there is the chorionic epithelium layer, which consists of cells, — cytotrophoblast. In the first months of pregnancy cytotrophoblast forms a continuous layer, individual cells disappear. In the center of the villi there are fetal capillaries.

The maternal part of the placenta is a thickened part of the decidua located under the chorionic villi. In the maternal part of the placenta there are formed recesses

Chapter 1

(lacunes) with immersed villi and circulating maternal blood, which washes them. Between these lacunes there are located decidual processes, to which anchoring villi attach. In these septa there run arteries that carry maternal blood to the intervillous space. The blood escapes from the arteries due to fusion of their walls under the influence of the villous syncytium. The venous blood flows from the intervillous spaces through the marginal sinus veins into the uterine veins. The maternal blood that washes the villi does not coagulate and mix with the fetal blood, which flows through the vessels located inside the villi.

The placenta provides metabolism between the organisms of the pregnant woman and the fetus, performing the trophic, endocrine, excretory, protective, and gas exchange functions, has antigenic and immunogenic properties. The placenta not only unites but also divides the genetically heterogeneous organisms of the mother and fetus, preventing immunological conflict.

Gas exchange between the blood of the mother and fetus occurs by means of diffusion through the endothelium of the capillaries, a layer of Langhans cells and villous syncytium. It occurs on the entire surface of the villi. In the process of gas exchange oxygen is transported to the fetus because its content in the blood of the fetus is lower than in the maternal blood. The placenta has the ability to regulate transport of oxygen and other gases to the fetal blood in case of their high content in the blood of the mother. In this way carbon dioxide is transported from the organism of the fetus into the mother's blood.

Trophic function of the placenta. Transport of proteins, carbohydrates, and fats from the maternal blood into the blood of the fetus is realized as a result of complex processes of enzymatic cleavage and synthesis of nutrients according to the needs of the developing organism. The placenta contains enzymes (protease, desaminase, alkaline phosphatase, etc.) that break down and synthesize proteins. In the placenta there is formed a specific thermostable alkaline phosphatase isoenzyme, whose content in the blood of the pregnant woman characterizes the degree of functional activity of the placenta. The syncytiotrophoblast and cytotrophoblast contain large amounts of RNA indicating a high activity of the process of protein synthesis. The placenta contains glutamate dehydrogenase, glutamine ethoxylone transaminase and other enzymes required to maintain a permanent set of amino acids in the body of the fetus. The processes of carbohydrate metabolism are intensive, indicating the presence of a considerable quantity of enzymes (diastase, invertase, esterase, lactase, carboxylase, etc.) and steroid hormones that affect carbohydrate metabolism in the placenta. The high content of lipids and lipolytic enzymes in the placenta indicates active exchange of lipids and neutral fats. Lipids, which are formed by cleavage of phospholipids (from the mother's blood), penetrate the placenta as well as products of enzymatic cleavage of neutral fats.

The placenta contains calcium, iron, phosphorus, copper, zinc, manganese, cobalt and other minerals. These substances come from the blood of the pregnant woman, are deposited in the placenta and are used according to the needs of the fetus that is developing. The content of phosphorus in the placenta increases with fetal development. It is believed that the elements are involved in the hormonal function of the placenta.

The placenta contains a significant amount of vitamins that also come from the mother's blood, are deposited in the placenta and then enter the organism of the

Fertilization, Embryogenesis, Critical Period of Ontogenesis

fetus. It has been established that the placenta can not only deposit vitamins, but also regulate the process of their transport.

Endocrine function of the placenta. The placenta is an endocrine gland, in which the processes of synthesis, secretion, and transformation of hormones are taking place. Hormones that are produced in the placenta condition the development of adaptive changes in the organism of the pregnant woman necessary for the growth and development of the fetus, for childbirth, and for preparation for the function of lactation. Hormones of the placenta are synthesized in the villous epithelium — syncytiotrophoblast and cytotrophoblast. Syncytium synthesizes and secretes steroids, cytotrophoblast — chorionic gonadotropin (hCG), whose level is very high during the early months of pregnancy. Its production lasts for a couple of months. hCG promotes the development and functional activity of the corpus luteum during pregnancy. In the placenta there is formed chorionic somatotropin, placental lactogen, prolactin, estrogen hormones, testosterone, hCG, adrenocorticotrop hormone (ACTH), progesterone. In the placental tissue there is found oxytocin, vasopressin, histamine, acetylcholine, prostaglandins, opioid peptides — endorphins and encephalins.

The placenta contains blood clotting factors and fibrinolysins (thromboplastin, fibrinolysin, calcium, etc.), which promote proper blood circulation in the intervillous space and stop bleeding after childbirth.

Antigenic and immunogenic properties of the placenta. All cellular and tissue elements that make up the placenta, hormones of embryonic and maternal origin (trophoblast, decidual cells, erythrocytes, leukocytes) are potential antigens. In the placenta one finds species-specific, group, tissue, organ, transient, and histocompatibility antigens (responsible for the induction of transplantation immunity reactions).

Tissues of the placenta and fetal membranes have differentiated group (according to the AB0-system) antigenic specificity: the decidual membrane contains the A- and B-factors of the mother's blood, the amnion — group antibodies of the fetal blood, and the chorionic tissue contains no antigenic substances that are found in the amnion and fetal blood. This makes obvious biological sense: immunologic "inertness" of the fetal part of the placenta relative to the maternal organism is an important factor of mutual protection of the maternal and fetal organisms against the development of immunological reactions. In addition, in the placenta there are determined almost 40 so-called proteins of the fetoplacental complex with immunomodulating capacity.

Barrier function of the placenta. The placental barrier is a set of morphological and functional features that determine the ability of the placenta to regulate the process of penetration of various substances from the mother's blood into the blood of the fetus and vice versa. Morphological substrate of the placental barrier is the epithelial lining of the villi and endothelium of the capillaries. Undamaged placenta inhibits transport of microbes and macromolecular compounds to the fetus. However, the barrier function of the placenta is limited. Nitrous oxide, alcohol, morphine, nicotine, atropine, mercury, arsenic, antibiotics, sulfanilamide drugs, barbiturates, salicylates, toxins, and antibodies get into the fetal blood through the placenta. Carbon dioxide, metabolic products, and antigens are transported from the fetus to the mother. It has been proved that fetal erythrocytes and leukocytes can get into the blood of the mother (in limited quantities). Infectious agents, viruses, protozoa (tox-

Chapter 1

plasma), pathogenic and nonpathogenic coccal microflora and other microorganisms penetrate into the fetal organism (due to pathological changes in the placenta).

Mature placenta looks like a disk with a diameter of 17 to 20 cm, it is 2–4 cm thick and weighs 500–600 g. The ratio of the placental weight to the fetal weight — the fetal-placental weight ratio (FPWR) — is 1/5–1/7. The placenta has two surfaces — maternal, adjacent to the uterine wall, and fetal, which is turned inwards, into the amniotic cavity. The fetal surface is covered with smooth, lucid amnion, under which there run the vessels that are in the radial direction from the place of attachment of the umbilical cord to the periphery of the placenta. The maternal placental surface is grayish-red, divided by more or less deep grooves into lobes consisting of multiple branched villi, which contain blood vessels. Such lobes are called *cotyledons*. The grayish tint of the maternal surface of the placenta is provided by the decidua, which covers the villi — the bulk of the placenta. The placenta is usually attached to the upper uterus, to the anterior or posterior wall; it is rarely attached to the uterine fundus or tubal angles.

Umbilical cord

The umbilical cord is formed of allantois, in which vessels run from the embryo to the chorion and which passes through the abdominal pedicle. The composition of the umbilical cord includes remains of the yolk sac.

Umbilical cord is a filamentary formation, in which there run two arteries and one vein that carry blood from the placenta to the fetus and vice versa. The umbilical arteries carry venous blood from the fetus to the placenta, the umbilical vein carries fetal arterial blood. The umbilical blood vessels are surrounded by gelatinous substance (Wharton's jelly) — mesenchyme, which contains a large quantity of the basal substance and small stellate embryonic connective tissue cells. The umbilical blood vessels are winding, that is why the umbilical cord is kind of twisted lengthwise. Outside the umbilical cord is covered with amnion. The umbilical cord connects the body of the fetus with the placenta, one its end is attached to the umbilical area of the fetus, the other — to the placenta. There is differentiated central attachment of the umbilical cord to the placenta (to its central part), lateral and marginal. Rarely, the umbilical cord is attached to the fetal membranes (membranous attachment of the umbilical cord); in such cases, the umbilical blood vessels run to the placenta between the membranes.

The length and thickness of the cord change according to the gestational age. The length of the umbilical cord usually corresponds to the length of the fetal body: the length of the umbilical cord of a mature fetus is 50 cm on average, the diameter — about 1.5 cm. However, not infrequently the umbilical cord is longer (60–80 cm) or shorter (35–40 cm and less).

Afterbirth

The afterbirth consists of extraembryonic parts of the gestational sac providing two-way connection between the fetal and maternal organisms.

The afterbirth consists of the placenta, fetal membranes, and umbilical cord — provisional organs, which are interrelated anatomically and functionally and perform

Contents

Abbreviations	3
CHAPTER 1. Fertilization, Embryogenesis, Critical Period of Ontogenesis.....	5
Fertilization	5
Gametogenesis	5
Fertilization.....	7
Blastogenesis	8
Implantation	8
Embryogenesis	9
Placenta	11
Umbilical cord.....	14
Afterbirth	14
Critical periods of ontogenesis.....	15
<i>Test questions</i>	15
<i>Case Study</i>	16
CHAPTER 2. Changes in the Woman's Body during Pregnancy. Hygiene and Nutrition of Pregnant Women. Influence of Harmful Factors on Fetus.....	17
Changes in the Woman's Body during Pregnancy.....	17
Central Nervous System	17
Endocrine System	17
Immune System	19
Metabolism	19
Cardiovascular System	20
Hematopoietic Organs	21
Respiratory System	21
Acid-Base Condition	22
Digestive System	22
Urinary System	22
Supporting-Motor Apparatus	22
Skin	23
Weight	23
Mammary Glands	23
Genital Organs	23
Regimen and Hygiene of Pregnant Women	25
Pregnancy Nutrition	26
Influence of Harmful Factors on Fetus	26
<i>Test Questions</i>	27
<i>Case Study</i>	28
CHAPTER 3. Methods of Research in Obstetrics and Perinatology. Pregnancy Diagnostics and Management	29
History Taking	29
Objective Obstetric Examination	30
General Examination.....	30

Contents

Specific Obstetric Examination.....	30
<i>Test Questions</i>	49
<i>Case Study</i>	50
CHAPTER 4. Female Pelvis. Pelvic Floor. Fetus as an Object of Labor. Biomechanism of Labor in Cephalic and Breech Presentation	51
Female Pelvis.....	51
Pelvic Floor	52
Fetus as an Object of Labor	55
Biomechanism of Labor in Cephalic and Breech Presentation	57
<i>Test Questions</i>	66
<i>Case Study</i>	67
CHAPTER 5. Causes of Labor Onset. Expulsive Forces. Clinical Picture, Management and Pain relief of Labor	68
Causes of Labor Onset.....	68
Assessment of Biological Readiness of the Pregnant Woman's Body for Labor	70
Labor Precursors.....	71
Expulsive Forces.....	71
Clinical Picture and Management of Labor	73
Partogram Use in Labor Management	83
Labor Pain Relief	86
<i>Test Questions</i>	88
<i>Case Study</i>	89
CHAPTER 6. Physiology of the Puerperal and Neonatal Periods	90
Physiology of the Puerperal Period	90
Involution of Genital Organs	90
The Main Principles of Puerperal Period Management	92
Postpartum Care	92
Physiology of the Neonatal Period	94
Neonatal Period Management	97
<i>Test Questions</i>	101
<i>Case Study</i>	102
CHAPTER 7. Multiple Pregnancy	103
Types of Twins.....	103
Multiple Pregnancy Diagnostics	105
Multiple Pregnancy Management	107
Intrauterine Death of one Twin.....	108
Congenital Defects	108
Multiple Pregnancy Labor and Delivery.....	109
<i>Test Questions</i>	111
<i>Case Study</i>	111
CHAPTER 8. Deflexion presentation, Pelvic Presentation, and Malposition of the Fetus	113
Deflexion Presentation of the Fetal Head	113
Sincipital Presentation	113
Brow Presentation.....	115
Face Presentation	116
<i>Test Questions</i>	118
<i>Case Study</i>	119
Pelvic Presentation	120
Pelvic Presentation Etiology	121
Pelvic Presentation Classification	121

Contents

Pelvic Presentation Diagnostics	123
Pregnancy Management in Pelvic Presentation	124
Corrigent Gymnastics Methods	125
Pelvic Labor Course	127
Pelvic Labor Management	127
<i>Test Questions</i>	131
<i>Case Study</i>	132
Fetal Malposition	133
Diagnostics of Transverse and Oblique Fetal Lie	134
Clinical Course and Management of Pregnancy and Labor	135
<i>Test Questions</i>	136
<i>Case Study</i>	137
CHAPTER 9. Miscarriage and Postmature Pregnancy.....	138
Miscarriage	138
Miscarriage Classification	139
Clinical Course and Diagnosis of Miscarriage	139
Threatened Abortion	140
Incipient Abortion	141
Abortion in Progress	141
Incomplete and Complete Abortion	141
Missed Abortion.....	141
Miscarriage Treatment	142
Premature Labor	144
Postmature Pregnancy	146
Postmature Pregnancy Diagnostics	147
Obstetric Management of Postmature Pregnancy	148
<i>Test Questions</i>	149
<i>Case Study</i>	149
CHAPTER 10. Bony Pelvis Anomalies	151
Anatomically Contracted Pelvis.....	151
Anatomically Contracted Pelvis Classification.....	151
Diagnosis and Peculiarities of Biomechanism of Labor	153
Clinically Contracted Pelvis.....	156
<i>Test Questions</i>	158
<i>Case Study</i>	158
CHAPTER 11. Birth Traumas of Mother and Fetus.....	160
Birth Traumas of Mother.....	160
Vulvar and Vaginal Ruptures	160
Ruptures of Vulvar and Vaginal Varices.....	160
Vulvar and Vaginal Hematomas	161
Perineal Rupture.....	161
Cervical Ruptures.....	163
Uterine Rupture.....	164
Inversion of Uterus	168
Separation and Rupture of Symphysis	168
Postpartum Fistula.....	168
Birth Injuries.....	169
Cephalohematoma	169
Skull Gaps and Fractures.....	169
Intracranial Birth Injury	170
Birth Injury of Spinal Cord.....	170

ridmi
ТВІЙ УЛЮБЛЕНИЙ КНИЖКОВИЙ

КУПИТИ