ЗМІСТ

Forensic Medicine: textbook

Про книгу

The textbook briefly highlights both the history of forensic medicine and organization and arbitration principles of forensic medical examination. Forensic and medical thanatology issues as well as diagnostics of various environmental injuries and health conditions are scrutinized in view of current scientific advancements. The data on lager radiation injuries and information on biological factor influence on the human body are introduced. Peculiarities of examining the injured and accused parties and other persons are described according to the Criminal Code of Ukraine. Current possibilities of forensic medical examination of material evidence are considered. Legal aspects of health care provision and legal responsibilities of physicians as health care providers for malpractice are provided according to the Criminal Code of Ukraine. All the chapters end with a list of questions for self-control. For students of higher medical educational establishments, as well as for internship doctors and beginners at forensic medical expert examination.

B.V. MYKHAILYCHENKO
A.M. BILIAKOV
I.G. SAVKA

Forensic MEDICINE

TEXTBOOK

Third edition

APPROVED
by the Ministry of Education and Science of Ukraine as a textbook for students of higher educational establishments — medical universities, institutes and academies

RECOMMENDED
by the Academic Council of Bogomolets National Medical University as a textbook for students of medical universities with English language training

Kyiv
AUS Medicine Publishing
2022

UDC 340.6,134
LBC 58;67.99(2)93ya73
M69

Approved by the Ministry of Education and Science of Ukraine as a textbook for students of higher educational establishments — medical universities, institutes and academies (letter No. 1/11-11455, 6 December 2011)

Recommended by the Academic Council of Bogomolets National Medical University as a textbook for students of medical universities with English language training (minutes No. 12, 27 April 2017)

Authors:
B.V. Mykhailychenko, A.M. Biliakov, I.G. Savka

Reviewers:
Viktor Bachynskyi — D.M., Professor, Head of the Department of Forensic Medicine and Medical Law of Higher State Educational Establishment of Ukraine "Bukovinian State Medical University", Chernivtsi, Ukraine;
Olexandr Gerasymenko — D.M., Professor

Mykhailychenko B.V.
M69 Forensic Medicine : textbook / B.V. Mykhailychenko, A.M. Biliakov, I.G. Savka ; edited by B.V. Mykhailychenko. — 3rd edition. — Kyiv : AUS Medicine Publishing, 2022. — 224 p.
ISBN 978-617-505-899-2

The textbook briefly highlights both the history of forensic medicine and organization and arbitration principles of forensic medical examination. Forensic and medical thanatology issues as well as diagnostics of various environmental injuries and health conditions are scrutinized in view of current scientific advancements.

The data on lager radiation injuries and information on biological factor influence on the human body are introduced.

Peculiarities of examining the injured and accused parties and other persons are described according to the Criminal Code of Ukraine.

Current possibilities of forensic medical examination of material evidence are considered.

Legal aspects of health care provision and legal responsibilities of physicians as health care providers for malpractice are provided according to the Criminal Code of Ukraine.

All the chapters end with a list of questions for self-control.

For students of higher medical educational establishments, as well as for internship doctors and beginners at forensic medical expert examination.

UDC 340.6,134
LBC 58;67.99(2)93ya73

ISBN 978-617-505-899-2

CONTENTS

CHAPTER 8

FORENSIC MEDICAL TRAUMATOLOGY

A bodily injury or a trauma from the medical point of view is a violation of anatomical integrity or a physiological function of tissues, organs or systems caused by environmental factors, such as mechanical, biological, chemical and mental.

Due to their multiplicity and diversity the bodily injuries are classified depending on the influencing factors, features, consequences, etc.

8. 1. INJURY CLASSIFICATION AND PECULIARITIES

1. According to the character of the environmental factors the injuries can be divided into physical, chemical, biological and mental.

1. *The injuries caused by physical factors* include the following types of traumas: mechanical, electrical, thermal, radiation, barometric traumas.

2. *The injuries caused by chemical factors* include chemical burns and poisonings as well as effect of medicines and gaseous substances.

3. *The injuries caused by biological factors can be connected with the influence of fungi, bacteria, viruses, prions or antigens.*

4. *The injuries caused by mental factors* lead to a mental trauma as a result of fear, fright or a strong inquietude.

2. According to their peculiar features the injuries are divided into *anatomical* (wounds, abrasions, bruises, fractures, viscera damage) and *functional* (pain, shock, brain concussion).

3. According to their consequences the injuries can be fatal and nonfatal. *Fatal* injuries result in death of the person, and *nonfatal* injuries can be divided into severe, medium and mild bodily harms.

The main tasks that are to be solved when examining an injury include the following: establishment of the presence of injuries and the mechanism of their origin (identification of the traumatizing object, establishing the direction and sequence of its action), whether the injury was made when a person was alive, what are the exact time of the injury, the cause of death or definition of the severity degree.

When describing an injury a certain algorithm is observed that includes the following:

1) anatomical areas of the body and distances from the known anatomical reference points (lines of the anatomical areas and, in some cases, the height from the soles);

2) injury shape: linear, slit-like or resembling some geometric shapes and letter of the alphabet. Peculiarities of the wound edges are described (even, uneven, wavy, jagged, etc.), presence of abrasions, flattening in the wounds, peculiarities of the ends (acute, rounded, etc.);

3) injury size (length, width, depth). In case of L-shaped and radial wounds the length of individual raptures (rays) from the centre is measured;

4) the direction of the injury relative to the figures of a conventional clock dial;

5) colour, relief, presence of extra layers, the state of the neighbouring tissues. If there are several injuries, their positional relationship must also be identified.

8.2. BLUNT OBJECT INJURIES

Blunt objects can be divided into blunt weapon, blunt tools and blunt objects proper.

Blunt *weapon* means the objects intended exclusively to cause harm.

Blunt tools include the objects that are used in production, household, as the instruments of labour (a crow, a hammer, etc.).

Blunt objects proper are the objects that always surround people and do not have any specified application (a stick, a stone) or have some application (a chair) but do not belong to the weapon or instruments of labour.

According to the shape of the traumatizing surface the obtuse objects can be divided into the following types:

1) with predominantly flat surface (table surface, floor);

2) with flat limited surface (a hammer);
3) with spherical surface (a weight);
4) with cylindrical surface (a chain, a tube);
5) with a trihedral angle (a corner of a table);
6) with an edge or a dihedral angle (an edge of a brick).

The blunt objects include also some parts of a human body, i.e. a head, hands, legs, teeth.

There are four types of the blunt object action mechanism: blow, pressing, stretching and friction.

A blow is short-term influence of an blunt object upon a human body at right or almost right angle. It can cause bruises, abrasions, wounds, fractures, viscera ruptures.

Pressing is a prolonged one-way force action. Pressing can cause deformation of some body parts, injuries of viscera and bones.

Stretching is a prolonged multidirectional force action that can cause skin chaps and tears, lacerated wounds, tearing off of body parts and extremities.

Friction is influence of an blunt object upon a human body at acute angle. Friction can cause abrasions.

Among the most wide-spread injuries caused by blunt objects are the following: abrasions, bruises, wounds, fractures.

Abrasion is superficial crippling of epidermis or mucous epithelium that does not affect derma. A scratch is an injury very similar to an abrasion. This is a narrow abrasion of linear form whose width is not significant.

Forensic medical examination of an abrasion can help to find out the prescription of the inkury, the direction of force action, the traumatizing object. Moreover, an abrasion indicates the area of the force application, it is the evidence of struggle or self-defence. Abrasions are classified as light bodily injuries.

The time or age of an abrasion is established based on four healing stages:

The first stage. In the first hours the abrasion surface is wet, later it becomes dry and brown-red crust is formed that is situated lower than the unaffected skin for the first 12 hours after the trauma.

The second stage. By the end of 24 hours the crust comes to the same level as the unaffected skin and later it rises further.

The third stage. On the 5th or the 6th day the crust begins to exfoliate at the peripheral area.

The fourth stage. On the 7th—12th day epithelization is completed and the crust peels absolutely off. Beneath there is a spot of hypo- or hyperpigmentation.

The terms of healing depend on the injury localization on the body, its depth, size as well as on the age and the state of the person's health.

Direction of the force application is found out based on the characteristics of the abrasion edges: the beginning of an abrasion is almost always flat and the end is deepened. Sometimes epidermis may be torn into some flaps whose free edges are displaced towards the direction of the blow.

Fig. 17. **Striped abrasions with parallel scratches in case of a traffic accident**

The traumatizing object can be found out by means of some foreign particles on the abrasion surface (metal, wood, paint). Sometimes it can be defined by the specific shape of the abrasions, for example, striped abrasions with parallel scratches appear when the body is pulled against the road carpet in case of a traffic accident (fig. 17, the author A.H. Zavalnyuk).

A bruise is penetration of blood from damaged vessels into subcutaneous fatty cellular tissue or dipper tissues. Accumulation of blood by mucous membranes is called hemorrhage. Accumulation of blood in a newly formed cavity is a hematoma.

During a forensic medical examination of a bruise it is possible to find out the age and the traumatizing object. A bruise is a result of an influence of an obtuse object, its locatization does not always indicate the area of the blow because the bruise can spread itself below the place of the force application. Bruises belong to the light bodily injuries. Sometimes their shape and localization can reflect the peculiarities of the violent act (suffocation with hands).

The age of a bruise can be found out by the changes of its colour due to hemoglobin transformation. During the first hours the colour is cherry-red because hemoglobin is in the oxidation state. Later the colour changes into blue with reddish shades or bluish-crimson because hemoglobin turns into a new form. During 2—4 hours the bruise gradually loses its reddish colouring and becomes dark-blue. On the 3rd—5th day the colour changes into brown-green as a result of biliverdine formation, and on the 6th—7th day yellow colour appears connected with the formation of bilirubin.

As a rule, bruioses disappear completely in 1.5 weeks. However, modifications occur both in the intensity of colouring and the sequence of its changes that depend on the amount of blood, localization, skin thickness and the state of the person's health.

Hemorrhages under mucous membranes do not change their colour with time and remain red because oxygen from the air can easily get through the wet membranes. They disappear gradually by means of resolution and reduction of size.

The traumatizing object can be defined by the bruise shape id the traumatizing surface was specific, for example, a belt buckle, tire tread, etc.

While examining the bruises during an autopsy it is necessary to distinguish them from the livores mortis. Bruises are characterized by more distinct borders, they do not change their colouring when pressed by a finger. Clots of blood are detected at skin sections in underneath tissues. These clots are densely fixed and cannot be washed out with water and are not easily taken off with the back of a knife.

A wound is an injury of skin, mucous membranes and deeper tissues. Application of blunt objects can cause compound, torn, squashed, flapped and bitten wounds. However, they do have some common features: their edges are uneven, stripped, squashed, in the depth of the wound between its edges membranes of connective tissues (tissue bridgings) are visible (connective tissue fibers that are kept). If a wound is given in the hairy part of the head, then hair bridges are situated between its edges (fig. 18). And so such wound calls laceration.

The wound shape and peculiarities depend on the traumatizing surface:

— *if the surface is predominantly flat* then the wounds are zigzag-like, branched, with twisting, stripped and partially squashed edges and ruptures;



Fig. 18. **Hair bridges in the depth of a laceration**

— *if the wound is given by a flat limited surface* (square, round), the wound looks like a rupture with three or four rays running from the centre;

— *if it was made with an object that has limited surface,* for example, an edge (a rib) of the surface, the shape of the wound is L-lke;

—*blunt objects with spherical surface* mostly cause wounds with 3—4 rays, Y — or cross-shaped;

— *objects with cylindrical surface* cause wounds with rectangular, curved, slit-like, spindle-like shape with uneven wavy or squashed edges and tissue membranes;

— *objects with ribs* create wounds of linear shape with even or acute edges that can resemble chopped wounds.

Thus, the wound shape, state of its edges, ends and bottom allow establishing the type of the object that has caused the trauma and the mechanism of its action.

A wound heals with a formed scar of reddish-pink colour, it is dense and is united with the underneath tissues. A quite old scar is white, moderately dense and not united with the underneath tissues.

According to the degree of severity wounds belong to the light bodily injuries that cause short-term health impairment.

Viscera injuries with skin integrity maintained. When obtuse objects are applied with a significant force, they can cause injuries of both parenchymatous and cavitary organs. Depending on the blow force the injuries can be divided into contusions, splits, ruptures, tearing-off and crushing of an organ. Contusion, split, rupture and crushing take lace in case of a direct blow, and an organ can tear off of the force was applied indirectly, by the blow and shaking mechanism.

Bone fracture is a partial or complete impairment of its anatomical integrity. Bone fractures can be open, that are accompanied by impairment of skin integrity, and closed when skin integrity in the place of the fracture is not impaired.

Fractures are divided into direct (local) occurring in the place of the object influence and indirect (remote) that appear at some distance from the place of the force application (fig. 19).

Flat bone fractures. In case of direct force application the bone tissue is stronger for pressuring than to stretching, that is why the inner bone plate is broken first, then followed by the outer one. Due to this the edges of the inner bone plate are serrulated and the edges of the outer plate are large-toothed with spalling. If a strong blow was caused by an object with relatively small surface with distinct borders, the flat bone is chipped resulting in a depressed or buttonhole fracture.

A crack is a type of fractures when the surfaces of the damaged bone do not go apart. The direction of a crack (fracture line) coincides with the direction of the traumatizing force, con-

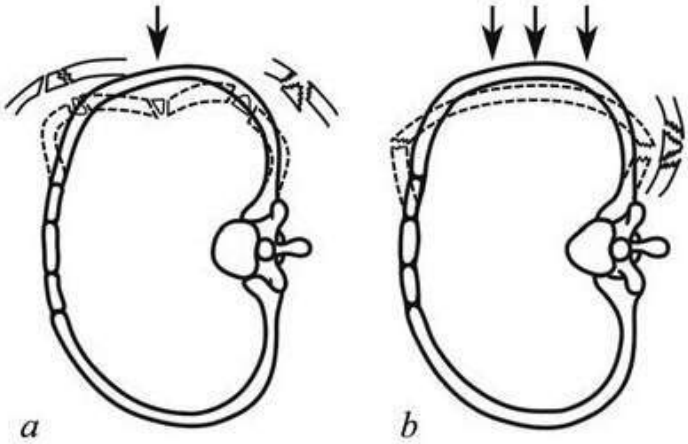

Fig. 19. **Mechanism of appearing and localization:**
a — of local; *b* — remote (indirect) rib fractures

sequently, the direction of the blow can be defined. When cracks are spread, acute angle is created whose top is directed towards the force action. According to the mutual localization of cracks the sequence of fracture appearing can be found out. Earlier cracks are never crossed by the cracks that emerged in the course of repeated injuries.

Face bone fractures are rather common in forensic medical practice.

The mechanism of lower jaw injury depends on the fact whether the jaws are pressed together or not. If the jaws are not pressed together, a blow from aside causes a fracture of the articular process at the opposite side from the blow. When the blow is directed from underneath, a fracture appears in the area of the lower jaw corner and the artricular process. The teeth pressed together fix the lower jaw well and this results in a fracture in the place of force application.

Upper jaw bone fractures appear, as a rule, when the jaws are not pressed together (fig. 20).

A blow on the level of the nasal cavity causes a fracture whose line separates the bones of visceral cranium from the cerebral cranium — *Le Fort 1* (fig. 20, a). A fracture of *Le Fort 2* type appears as a result of a strong blow on the level of the nose when the jaws are not pressed together. This fracture is a separation of the upper jaw bones at the area of its junction with other bones (fig. 20, b). If a blow is made from the front and the jaw are not pressed together, a fracture of *Le Fort 3* type is created. This is an upper jaw fracture that goes across above the alveolar process along the lower edge of the nasal opening (fig. 20, c).

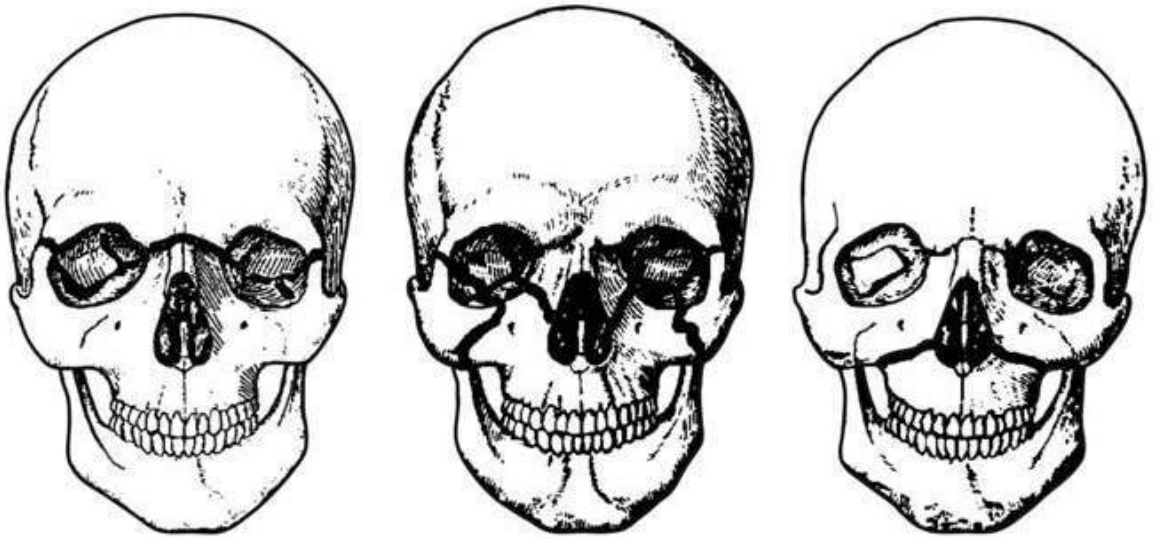

a *b* *c*

Fig. 20. **Upper jaw fractures:**
a — type 1; *b* — type 2; *c* — type 3

Rib fractures can appear both in the place of the force application — direct or local fractures — and at some distance (indirect or remote fractures) (see fig. 19).

At the place of the force application the fracture line on the outer rib surface is uneven, large-teethed with chips and splitting. The fracture line on the outer surface approaches the direct one.

A remote rib fracture is also caused by rib deformation but in the opposite direction. As a result the fracture line on the outer rib surface is almost even and on the inner surface it is large-teethed.

Tubular bone fractures depending on the mechanism of their appearing can be a crushed bone, non-shattered, slanting, screw-like, etc.

Since bones are stronger for pressuring than for stretching, when bended they are destroyed in the place of the strongest stretching, i.e. at the convex side. A crack that appears and spreads in the direction of the concave side is the place of the force application. If the crack is branched, a fragment of a triangular shape is created.

Injuries cause by falling from height. During a forensic medical examination special attention is paid to non-conformities of the inner and outer injuries, the former being much more numerous because organs can rupture or tear off, fractures can be numerous. The signs of a general body shaking are also looked for, i.e. hemorrhages and ruptures at the root of the lungs, vessels, heart base, bleedings into ligaments and under the lever capsule, spleen, into an adipose capsule.

If the body falls from height directly, one-sided localization of injuries is predominantly observed. They can also be double-sided as a result of hitting some objects while falling down.

If a person falls onto his/her feet, fractures of calcaneal bones, bones of ankles, thighs, compression fractures of vertebrae are observed. If a person falls onto his/her buttocks, fractures of pelvic bones, compression fractures of spine on the level of lower thoracic and loin vertebrae, basal skull fracture are typical. In case a person falls onto his/her head, numerous fractures of calvarium and basal skull are observed.

Falling on a plane is falling from the body height, i.e. from the standing position.

In this event injuries are caused by occiput hits. On the back of the head abrasions, bruises, rarely wounds can be found. Lineal fractures of occipital bones are the most common. Occipital cerebral contusion is not very wide-spread in comparison with the injuries of the countercoup area (frontal cortex, anterior areas of temporal cortex) where focuses of massive cerebral contusion emerge (fig. 21, 22).

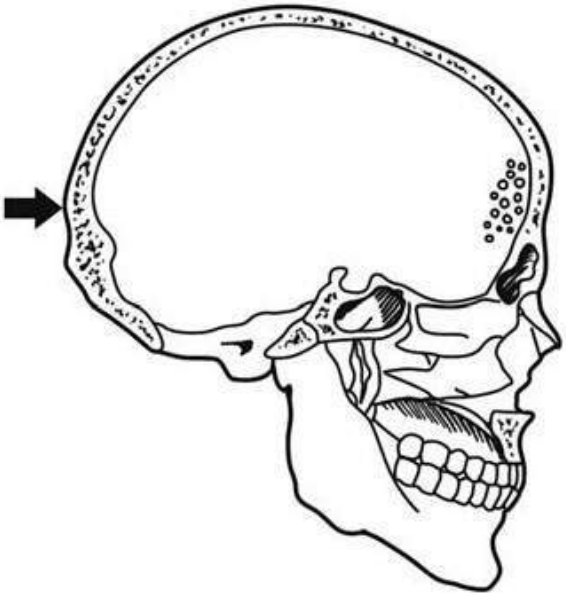

Fig. 21. **Mechanism of frontal cortes damage. Falling on a plane**

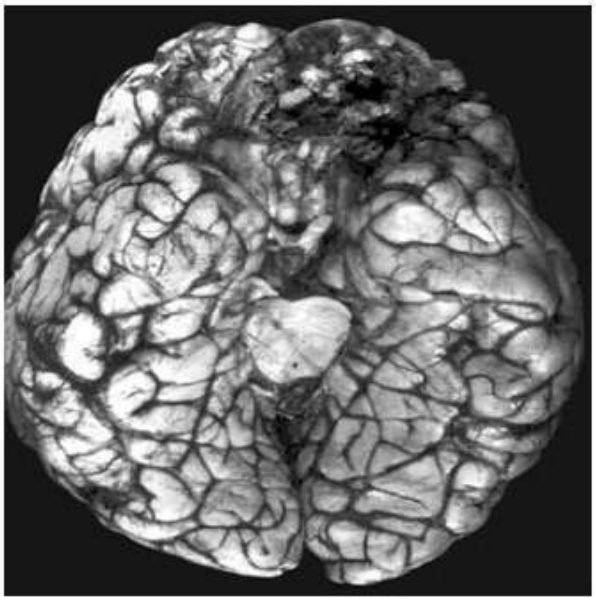

Fig. 22. **Focuses of massive contusions in frontal cortex** (by M. Polyschuk)

8.3. TRAUMATISM AND ITS TYPES

Traumatism is appearing of homogenous traumas in people under similar working and home conditions. The following types of traumatism are distinguished: transportation, production, industrial and agricultural, home, school, sports, military traumatism, etc.

Forensic experts have to carry out an examination in the connection with injuries due to household and transportation traumatism.

8.4. TRANSPORTATION TRAUMATISM

A transportation trauma is a type of mechanical injuries caused by external or internal parts of transport vehicles that are moving or by falling from the moving vehicles.

Depending on the mode of transport that causes the injuries there can be distinguished car, motorcycle, tractor, tram, railway, aviation and water transport traumas.

Car traumas. A car trauma is a set of injuries in drivers, passengers and passersby as a result of vehicle movement.

All the numerous injuries that appear in the case of a car trauma can be divided into specific, typical and atypical.

Specific injuries are contact injuries that reflect the shape, design and size of the car parts and details when affecting the clothes or the body of a person (imprints of headlights, tread, etc.). They help to identify the type and sometimes even the make of the car.